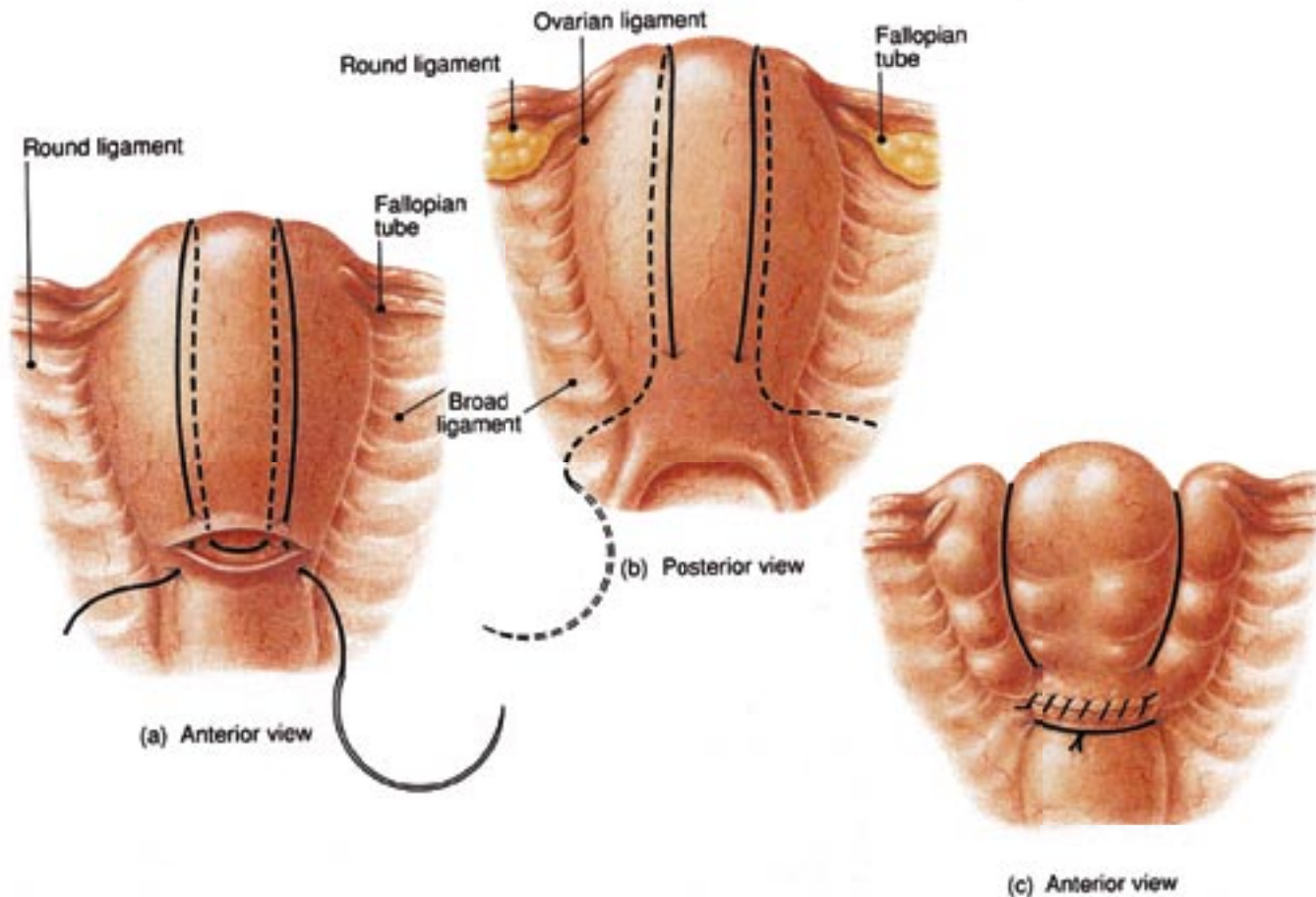


B-Lynch Suture Diagrams



Parts (a) and (b) demonstrate the anterior and posterior views of the uterus showing applications of the B-Lynch Brace Suture. Part (c) shows the anatomical appearance after competent application. (Illustrations by Mr. Philip Wilson FMAA, AIMI, based on the authors' video record of the operation.)